

# Case Spotlight

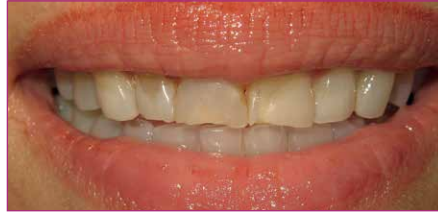Dr. Pamela Marzban DDS, FAGD, LVIF



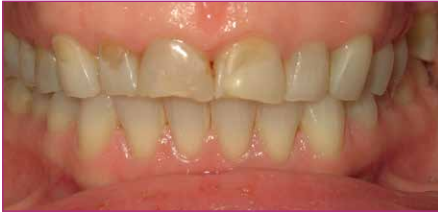Dr. Pamela Marzban graduated with a Doctor of Dental Surgery (DDS) with Honours/Distinctions from the Medical College of Virginia in 2000. Having grown up in Northern Virginia, she purchased a practice in Burke, VA in 2002 specializing in cosmetic dentistry, advanced implant technology and neuromuscular dentistry. A fellow of the Las Vegas Institute for Advanced Dental Studies, Dr. Marzban has completed Core curriculum and PAT courses. She is a Fellow in the Academy of General Dentistry, and a member of the American Academy of Cosmetic Dentistry, International Association of Comprehensive Aesthetics, American Dental Association, and Virginia Dental Association. Dr. Marzban is also a clinical instructor at Virginia Commonwealth University and teaches there part time.



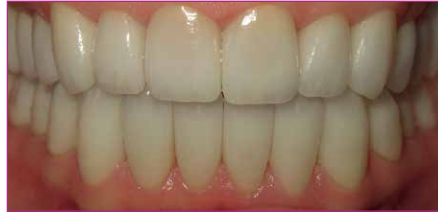▲ Full face Before.



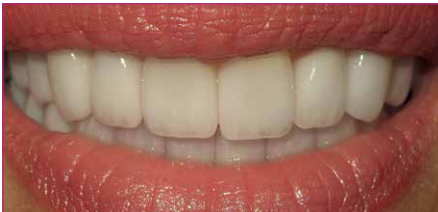▲ Close-up of pre-treatment natural smile.



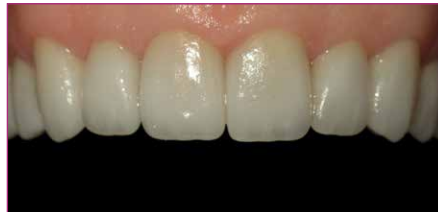▲ Retracted view, pre-treatment.



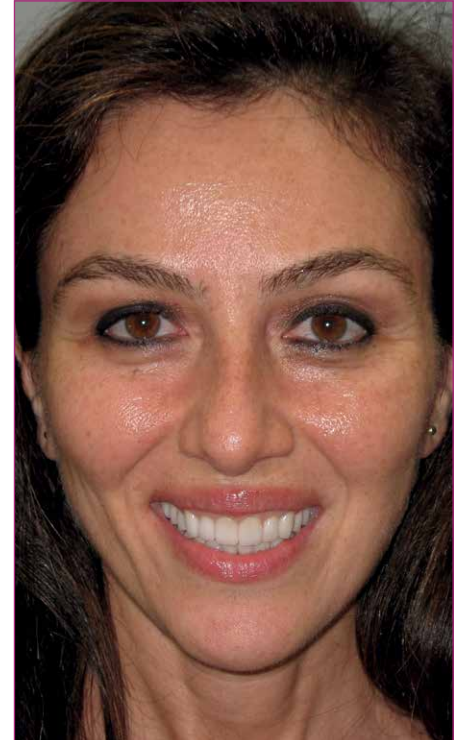
▲ Retracted view, post-treatment  
– Note lower restorations are longer.



▲ Close-up of beautiful new smile.



▲ Note the texturing and translucency achieved



▲ Full face After.

“As a dental professional, this patient was troubled by her severely worn dentition and wanted to rehabilitate her bite for cosmetic reasons. Yet as an orthodontist, while her teeth were perfectly straight, she knew she was still grinding her teeth as a bruxer/clencher and saw the evidence of wear, eventually cracking #14 and losing the tooth. This was the tipping point causing her to move ahead with Full Mouth rehabilitation, beginning with her upper arch as soon as possible.

This patient illustrates several important points about treatment planning with Full Mouth cases. When she smiles naturally, the patient has a lot of maxillary display – your typical ‘gummy smile’. This results in challenges when you open the bite – the danger is you will end up with a “toothy and gummy” smile that is certainly not the desired optimal aesthetic end result both patient and clinician are looking for. In this instance, this was remedied by making her lower teeth longer to balance the smile. In addition, we should all bear in mind that opening the smile can also have a dramatic

impact on the overall facial aesthetics of the patient. Opening the vertical dimension can result in a noticeable change in lip posturing, altering the way the lip drapes and often resulting in a patient that looks much younger after treatment.

While a bruxer/clencher, she was completely asymptomatic and did not suffer from any TMJ pain. We started her treatment by taking a full set of diagnostic x-rays and a myobite to determine her comfortable bite position, which showed she was overclosed by 5.4 mm. A Removable Lower Orthotic was placed for 4 months to correct the patient’s jaw alignment and to calibrate proper vertical positioning. After conducting a K-7 neuromuscular study to ensure her new bite was comfortable, Aurum Ceramic prepared a Diagnostic Wax-up as per their ACCES™ system. We prepared and seated her maxillary arch and transitioned to a Fixed Lower LVI Orthotic for eleven months. The maxillary set of temporaries was created from the wax-up from the bite transfer.

The patient allowed me complete freedom on the color and texturing of her restorations but wanted final say on the translucency. Her lower arch was prepared and finished. With both arches I used the Aurum Ceramic Advanced Esthetic (AE) Team® the Prep Indices and Bite Stents. The upper and lower arches were restored with a combination of single IPS e.max® crowns due to existing restorations; IPS Empress® veneers (on #6-8,10-11 and #22-27) as a conservative option as her teeth did not require full crowns; and a custom implant-retained Zirconia abutment and IPS e.max® crown on #14.

As the “After” photo shows, the texturing and translucency on this case is looks amazing. The restorations look truly natural. With a lot of texturing, when the light hits the moisture (i.e., saliva) on the dentition, it really gives the teeth dimension. The porcelain work from the Aurum Ceramic Advanced Esthetic (AE) Team was truly beautiful and really enhanced the final result.”